

Histological Study of the Effect of Chemotherapy with 5-Fluorouracil on Normal Liver and Kidney of Mice

Heba Nageh Gad EL Hak¹, Tarek Ibrahim Saad Moawad², Gamal Abdel-Aty Hafez³

^{1,2}Zoology Department, Faculty of Science, Suez Canal University, Ismailia, Egypt.

³Pathology Department, Faculty of Medicine, Suez Canal University, Ismailia, Egypt.

Abstract: To determine the histological changes induced by the human therapeutic dose of 5-Fluorouracil (5-FU) and study the histological effects of a single intraperitoneal injection of one tenth, three tenths and five tenths 5-FU LD₅₀ on liver and kidney of healthy mice and to show if these changes are irreversible or not after stopping the treatment. For testing the effects of the drug human therapeutic regime, 18 mice were allocated in six cages (3 mice each); one acted as a control and five acted as a treated group. Treated group received the following treatment through intraperitoneal injection, an initial dose (12 mg/kg 5-FU) was injected intraperitoneally for three consecutive days and a maintenance dose (15 mg/kg 5-FU) was injected intraperitoneally once a week for three weeks. For testing effects of a single intraperitoneal injection of one tenth, three tenths and five tenths 5-FU LD₅₀, the mice were randomized into four groups (one control group and three treated groups) 10 mice each. The treated groups received 50, 150 and 250 mg/kg 5-FU through intraperitoneal injection, respectively. The human therapeutic regime induced histological change only in liver. The treated groups received 50, 150 and 250 mg/kg 5-FU, fatty degeneration and portal area inflammatory cells infiltration were noticed after one week. Liver multinucleated giant cells were detected only in histological sections of mice that received 150 mg/kg. The 250 mg/kg 5-FU induced liver apoptosis. Kidney tubular necrosis was induced by a single injection of 150 and 250 mg/kg 5-FU. The 5-FU human therapeutic regime induced no histological changes in the mice studied organs except for the liver. It induced liver focal necrosis and hydropic degeneration. While, the liver hydropic degeneration disappeared later on, the liver focal necrosis persisted. Using higher doses induced histological change to the liver and the kidney and these pathological changes persisted.

Keywords: 5-FU, liver, kidney, mice.

I. INTRODUCTION

Chemotherapy is the use of cytotoxic drugs to control or eliminate cancer. The drugs are administered to the body by a variety of routes with the aim to achieve a certain concentration in the bloodstream that will act systematically to kill cells. This means that both cancerous and normal cells will suffer due to some effects of these drugs. The intention of the drug administration is to eradicate the tumors or, at least, to control the proliferation of cancerous cells. However, the treatment has toxic side effects on the rest of the body. The success of chemotherapy therefore depends crucially on maintaining sufficient damage to the tumors while effectively managing the toxic side effects^(1,2,3,4).

5-Fluorouracil (5-FU) is an antimetabolite chemotherapy drug, is used for a variety of solid cancers^(5,6) including liver carcinoma, breast carcinoma and colorectal carcinoma^(7,8). 5-FU is a derivative of uracil. It is fluorinated at position 5 on the ring uracil. There are three main mechanisms by which 5-FU is thought to exert its cytotoxic effects on cancer cells⁽⁸⁾. These are inhibition of the activity of thymidylate synthase, DNA-directed cytotoxicity and RNA-directed cytotoxicity⁽⁹⁾.

In the present experimental work, we studied the effects of human therapeutic dose of 5-FU and one tenth, three tenths and five tenths 5-FU LD₅₀ on the liver and the kidney of healthy mice by light microscopy. The purpose of this study was to discern any pathological changes caused by 5-FU administration.

II. MATERIALS AND METHODS

2.1. Chemicals: Neoflur (5-FU) is a product of Mumbai central India and is supplied as a 250 mg vial of the drug dissolved in 5 mL water, each 1 ml of the resulted solution contains 50 mg 5-FU. 5-FU was diluted in injectable water for all doses and is used immediately after dilution.

2.1.1. Animals: Male adult albino mice obtained from National Research Centre, Cairo, were used in all experiments conducted in this study. At the beginning of each experiment the mice weighing between (20-30 gm) were kept in cages under standard conditions, Mice were housed in plastic cages, wire topped with sawdust bedding. Mice were fed on standard diet and tap water was given *ad libitum*. They were acclimatized to their place for one week before the experiment. Animals were randomly allocated into two separate experiments.

2.2. Experimental design:

2.2.1-Testing the human therapeutic dose in mice:

The mice were randomized into six cages (3 mice each) and received the following treatment through intraperitoneal injection, an initial dose (12 mg/kg of 5-FU) was injected for three consecutive days and a maintenance dose (15 mg/kg of 5-FU) was injected once a week for three weeks. This method of treatment is recommended by the drug manufacturer for human patients.

Cage (1): control group received no treatment, Cage (2): mice sacrificed four day after the initial dose, Cage (3): mice sacrificed one week after the last maintenance dose, Cage (4): mice sacrificed five weeks after the last maintenance dose, Cage (5): mice sacrificed three months after the last maintenance dose, Cage (6): mice sacrificed four months after the last maintenance dose. Tissue samples of the liver and kidney were taken and examined for histological changes.

2.2.2-Testing one-tenth, three-tenths and five-tenths 5-FU LD₅₀:

The mice were randomized into four groups (10 mice each) and received the following doses through intraperitoneal injection: Group (1): control group received injectable water, Group (2): received a single dose of 50 mg/kg of 5-FU (one-tenth LD₅₀ of the drug), Group (3): received a single dose of 150 mg/kg of 5-FU (three-tenths LD₅₀ of the drug), Group (4): received a single dose of 250 mg/kg of 5-FU (five-tenths LD₅₀ of the drug). For the group that received 50 mg/kg of 5-FU, 3 mice were sacrificed after 7, 15, 45 days and one mouse were sacrificed after 2 months. Five mice which received 150 mg/kg 5-FU, died between the 5th and the 15th days after injection, histological samples were taken from one mouse at 7, 15, 45 days and 2 months. During the period of the experiment, all mice receiving 250 mg/kg 5-FU died between the 4th and 13th days. Histological samples of liver and kidney from both dead and sacrificed mice were examined for histological changes.

2.3-Histological preparation:

Tissue samples were fixed in Bouins fluid, embedded in paraffin and examined with Harris Haematoxylin and Eosin ⁽¹⁰⁾.

III. RESULTS

3.1-Testing the human therapeutic dose in mice:

Liver sections of mice which received 12 mg/kg 5-FU for three consecutive days and sacrificed after four day showed hydropic degeneration of most hepatic cells and focal necrosis in the central vein zone (plate 1). Liver sections of mice which received both the initial and maintenance doses of 5-FU and sacrificed after one week, five weeks, three months and four months of the last maintenance injection showed focal necrosis near the central vein (plate 1).

There were no apparent histopathological changes in kidney sections of mice which received the initial dose of 12 mg/kg of 5-FU for three consecutive days and sacrificed on the fourth day after the last injection, as well as those mice which received both the initial and maintenance doses and sacrificed at one week, five weeks, three months and four months after the last maintenance injection (plate 2).

3.2-Testing one-tenth, three-tenths and five-tenths 5-FU LD₅₀:

Some histopathological changes, which appeared in both the central and peripheral areas of the hepatic lobules, were observed in the liver sections of mice which received a single intraperitoneal injection of 50, 150 and 250 mg/kg 5-FU. These changes are hydropic degeneration, fatty degeneration and scattered focal areas of necrosis as well as infiltrations of inflammatory cells in the portal tracts (plate 3). No fibrosis was seen in the portal area. Apoptosis of some hepatic cell appeared in mice which received 250 mg/kg 5-FU and giant multinucleated cell appeared in Liver sections of the mice which received 150 mg/kg 5-FU and taken 6 days and 7 days after the injection (plate 3).

Kidney sections of mice which received a single intraperitoneal injection of 50 mg/kg showed no pathological changes. Tubular necrosis with pyknotic nuclei was observed in kidney sections of mice which received a single intraperitoneal injection of 150 or 250 mg/kg (plate 3).

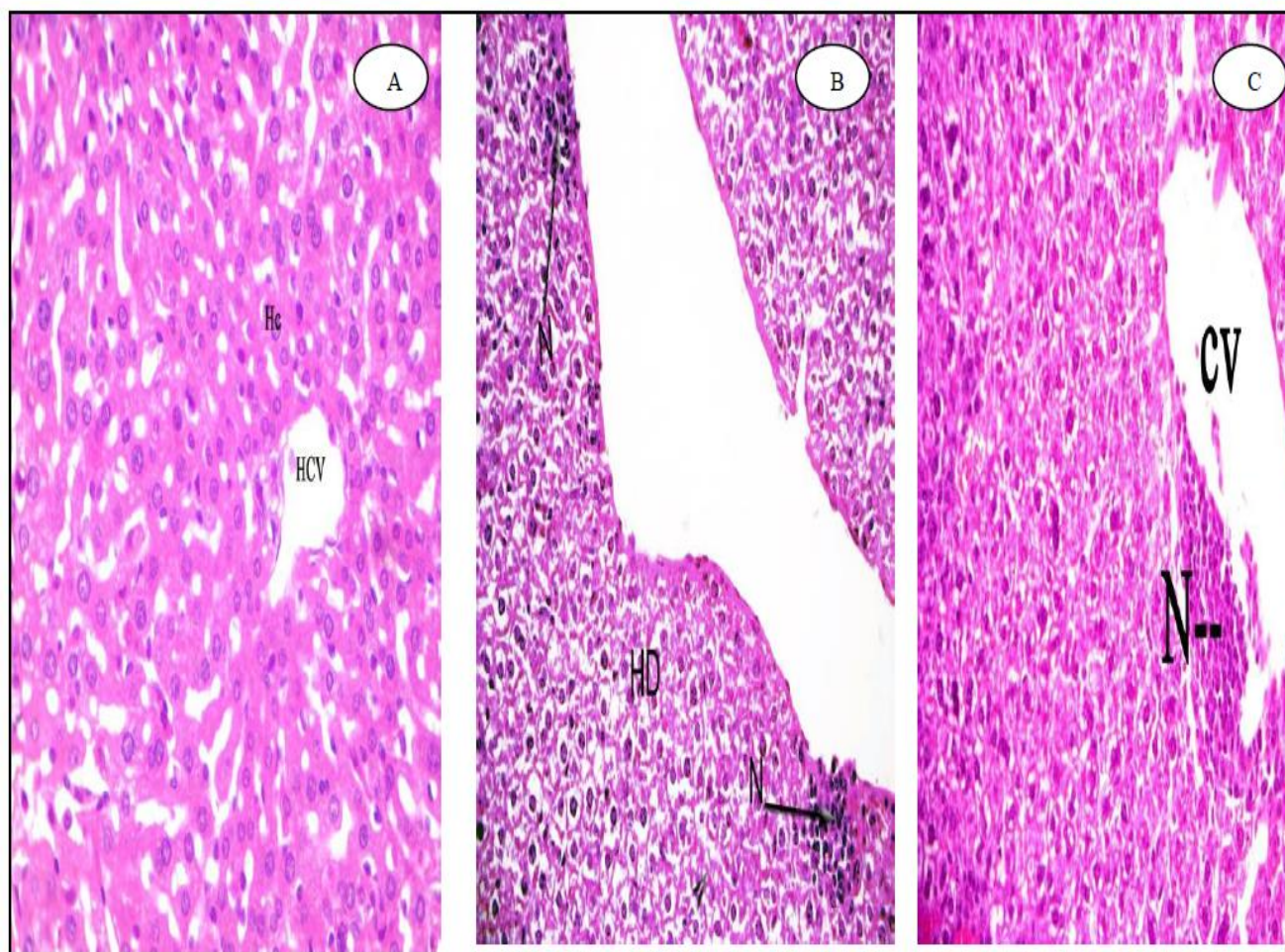


Plate (1): (A) hotomicrograph of a liver section of a control mouse showing normal liver architecture. Abbreviations: HCV: hepatic central vein and Hc: hepatocytes. H&E stain, 400X. (B): Liver section of a mouse treated with the initial dose of the human therapeutic regime (12 mg/kg 5-FU for three consecutive days) and sacrificed 4 days from the last injection. It shows hydropic degeneration of the hepatocytes (HD) as well as focal necrosis (N) in the central vein zone. H&E stain, 200X. (C): Liver section of a mouse treated with the human therapeutic regime for 5-FU and sacrificed 4 days from the last injection showing focal necrosis (N) in the central vein zone. H&E stain

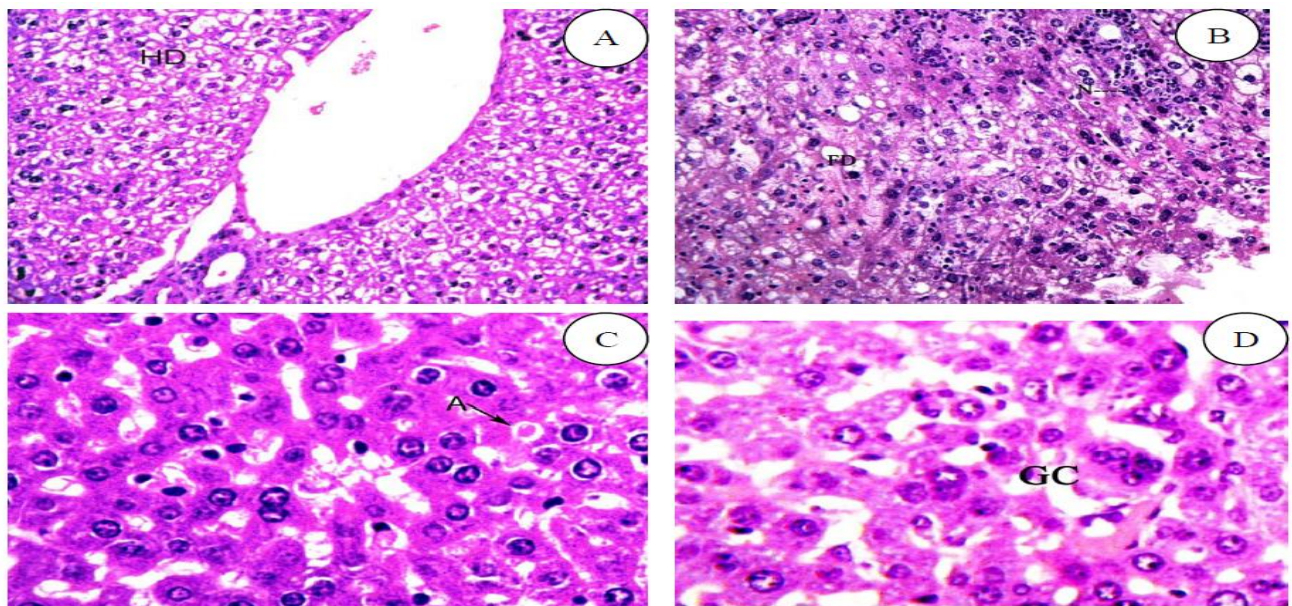


Plate (2): (A): Mouse liver section showing hydropic degeneration (HD) in the peripheral zone induced by a single intraperitoneal injection of 150 mg/kg 5-FU. Sample was taken after 15 days of the injection. H&E stain, 200X. (B): Photomicrograph of mouse liver section showing fatty degeneration (FD) and focal necrosis (N) resulted from a single intraperitoneal injection of 150 mg/kg 5-FU. Sample was taken at the 15th day of the injection. H&E stain, 400X. (C): Photomicrograph of mouse liver section showing apoptotic cell (A). Sample was taken from a 250 mg/kg 5-FU intraperitoneally injected mouse which dead 6 days from the injection. H&E stain, 400 X. (D): Liver section of a treated mouse which received a single intraperitoneal injection 150 mg/kg 5-FU and dead 6 days from the injection showing giant multinucleated cell (GC). H&E stain, 400 X.

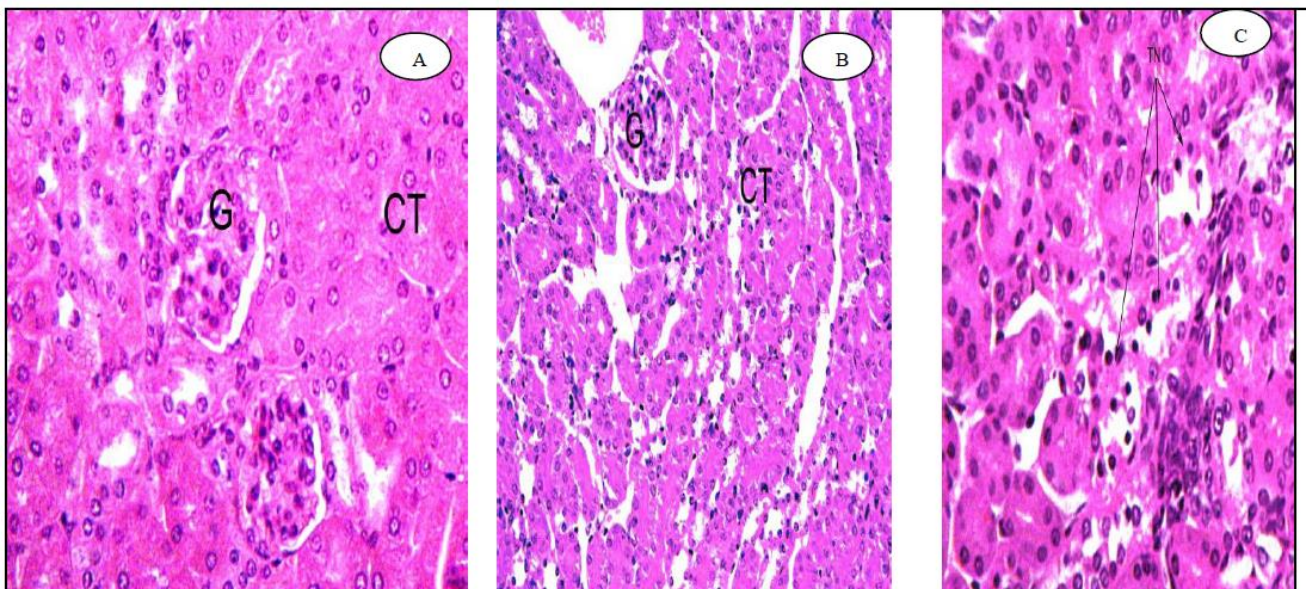


Plate (3): (A) control mouse kidney section showing normal histological structure with normal glomeruli (G) and convoluted tubules (CT). H&E stain, 400 X. (B) Kidney section of a treated mouse which received the human therapeutic regime for 5-FU and sacrificed after one week from the last maintenance injection showing normal histological structure with normal glomeruli (G) and convoluted tubules (CT). H&E stain, 100 X. (C) Kidney section of a treated mouse which received a single intraperitoneal injection of 150 mg/kg 5-FU and sacrificed 7 days after the injection showing Tubular necrosis (TN) H&E stain, 200 X.

IV. DISCUSSION

In this study, 5-FU was tested to find out its effect on the liver and the kidney. From the present findings, it is clear that the pathological damages were more evident in the liver than the kidney when the drug was administered in small doses. While when higher concentrations of the drug were used, the kidney showed pathological alterations. This suggests that there is a selective differential response for different organs with regards to the damage effects of 5-FU. However, this may be due to the fact that the liver has higher absorption of 5-FU compared with other organs as explained by ⁽¹³⁾ and ⁽¹⁴⁾. Available literature did not give a full account of the pathological changes of the selected organs at these doses and in this species. We may conclude that the severity and the onset of these changes depend mainly on the dosage and/or the time of treatment. These results were not in agreement with the studies conducted by either ⁽¹⁴⁾ or ⁽¹⁶⁾. William ⁽¹⁴⁾ found no hepatic damage after the perfusion of 100, 250 and 500 mg/kg 5-FU to pigs; also Zafiriou *et al.* ⁽¹⁵⁾ found no hepatic or renal damage after bolus infusion of 15 mg/kg 5-FU via the inferior vena cava to rats. Moreover, Xing and Li ⁽¹⁶⁾ again found no hepatic pathological changes in rats after perfusion of 150 mg/kg 5-FU. These differences may be due to various doses, species and route of administration that were used in each experiment.

Recent work demonstrated that the liver of the mice which received the human therapeutic regime of 5-FU suffered from hydropic degeneration of most of hepatic cells and focal necrosis after four days of receiving the initial dose. Focal necrosis in the central zone was detected after one week, three weeks, five weeks, three months and four months of receiving the last maintenance doses. When 5-FU was administered to mice in the form of a single intraperitoneal injection of 50, 150 and 250 mg/kg, the liver showed hydropic and fatty degeneration, necrosis, prominent apoptosis, multinucleated giant hepatocytes and infiltration of inflammatory cells in the portal area. These pathological changes are comparable with the findings of studies on rats: Nagasue *et al.* ⁽¹⁷⁾ who found fatty degeneration and degenerative changes of the hepatocytes at the peripheral area when 20 mg/kg 5-FU was administered intravenously; Zafiriou *et al.* ⁽¹⁵⁾ who found necrotic foci of the hepatocytes with polymorphonuclear infiltrations in the surrounding hepatic parenchyma after bolus infusion of 15 mg/kg 5-FU via the inferior vena cava and Xing and Li ⁽¹⁴⁾ who found degenerating hepatocytes and necrotic lesions in the liver after perfusion the rats with 200 and 500 mg/kg of 5-FU. Again the present findings are in line with the findings of studies on pigs, as previously mentioned by William ⁽¹⁴⁾ who found widespread hepatic necrosis with acute and chronic inflammation in two pigs after perfusion with 1000 mg/kg 5-FU. The liver histopathological changes detected in the present study are also in agreement with those of Nagasue *et al.* ⁽¹⁷⁾; Rubbia-Brandt *et al.* ⁽¹⁸⁾; Aloia *et al.* ⁽¹⁹⁾; Karoui *et al.* ⁽²⁰⁾; Vauthey *et al.* ⁽²¹⁾; Aloysius *et al.* ⁽²²⁾; Jennica *et al.* ⁽²³⁾ and Kandutsch *et al.* ⁽²⁴⁾ who studied the effect of 5-FU in human patients. It is believed that such pathological damage could be attributed to the toxic effects of the drug on the hepatic cells; even if it is administered at very low dose. When 5-FU was administered to mice with the initial dose of 12 mg/kg of 5-FU for three consecutive days and 15 mg/kg of 5-FU once a week for three weeks as a maintenance dose and 50 mg/kg in the form of a single injection, the kidney appeared normal similar to that of the control animals. This is in agreement with Zafiriou *et al.* ⁽¹³⁾ who found that 5-FU did not cause any kidney abnormalities in rats after bolus infusion of 15 mg/kg 5-FU via the inferior vena cava. While in the present study, when 5-FU was used in higher doses (150 and 250 mg/kg); it resulted in marked tubular necrosis of the kidney.

In conclusion, the 5-FU human therapeutic regime is safe to the kidney and liver for a large extent while the higher doses are not safe and must be used carefully under close medical supervision.

REFERENCES

- [1] H.M. Pinedo and, G Giaccone. Chemotherapy. Lancet; 349: 7-9, 1997.
- [2] J. Verwei and M.J.A De Jonge. Achievements and future of chemotherapy. Eur. J. cancer, 36: 1479-1487; 2000.
- [3] M., Ozturk, B. Barta, N. Gurler, Y. Ozk, A. Kars; Kansu, E.; E.Baltal, and G. Tekuzman, Modified ESHAP as salvage chemotherapy for recurrent or refractory non Hodgkin lymphoma: results of a single centre study of 32 patients. Chemotherapy; 48: 252-25, 2002.
- [4] M. Colovic; A. Bogdanovic; G. Jankovic; Kragul, N. Jac. And N. Suvajdzic, Long-term survival in acute lymphoblastic leukemia in adults treated according to the LALA87 protocol. Chemotherapy; 2003, 49: 138-145.

- [5] H., Takeda, M. Haisa,; Y. Naomoto; R.Kawashima,; K. Satomoto,; T.Yamatuji, and N.. Tanaka, Effect of 5-fluorouracil on cell cycle regulatory proteins in human colon cancer cell line. *J. pn. J. Cancer Res.*, 90(6): 677-684, 1999.
- [6] E. Tokunaga, S. Oda, M. Fukushima, Y. Maehara, and K. Sugimachi, Differential growth inhibition by 5-fluorouracil in human colorectal carcinoma cell lines. *Eur. J. Cancer*, 36(15): 1998-2006, 2000.
- [7] K., Ghoshal, and S.T., Jacob, An alternative molecular mechanism of action of 5-fluorouracil, a potent anticancer drug. *Biochem. Pharmacol.*, 53(11): 1569-1575, 1997.
- [8] H.H., Backus, H. M. Pinedo, D. Wouters, C.M. Kuiper, G. Jansen, C.J. van Groeningen, and G.J. Peters, Differences in the induction of DNA damage, cell cycle arrest and cell death by 5-fluorouracil and antifolates. *Oncol. Res.*, 12(5): 231-239, 2000.
- [9] A.F Sobrero; C. Aschele, and J.R. Bertino, Fluorouracil in colorectal cancer--a tale of two drugs: implications for biochemical modulation. *J. Clin. Oncol.* , 15(1): 368-381, 1997.
- [10] Gurr, E. 1956. *A Practical Manual of Medical and Biological Staining Techniques*. Leonard Hill, London.
- [11] S.Takahashi, Y. Ogata and H.Miyazaki Aggressive surgery for pancreatic duct cell cancer: feasibility, validity, limitation. *World J. surg.*, 19: 653-660, 1995.
- [12] G.W.M. Visser, G.C.M. Gorree, G.J. Peters, and J.D.M. Herscheid, Tissue distribution of ¹⁸F-5-Fluorouracil in mice: effects of route of administration, strains, tumor and dose. *Cancer chemother. Pharmacol.*, 26:205-209, 1990.
- [13] F.S Wiliam. Isolation-perfusion of the liver with 5-Fluorouracil. *Ann. Surg.*, 201(3): 37-343, 1985.
- [14] G. Zafirou, A. Grekou, P. Stravoravdi, K. Natsis, and A. Barich, Histological and Ultrastructural study of the effect of chemotherapy with 5-Fluorouracil on normal liver of Wistar rats. *Chemotherapy*, (48): 298-302, 2002 .
- [15] X. Xing and H. Li, Isolated liver perfusion for reginol chemotherapy in rats.Hepatobiliary pancreat. *Dis. Int.*, (6): 388-392, 2007.
- [16] N. Nagasue,; M Kobayashi. and A. Iwaki, Effect of 5-Fluorouracil on liver regeneration and metabolism after partial hepatectomy in the rat. *Cancer*, 4: 435-443, 1978.
- [17] L.; Rubbia-Brandt, V., Audard, P. Sartoretti, A.D. Roth, C. Brezault, M. Le Charpentier, B. Dousset, P. Morel, O. Soubrane, S. Chaussade, G. Mentha, and B.Terris, Severe hepatic sinusoidal obstruction associated with oaliplatin-based chemotherapy in patients with metastatic colorectal cancer. *Ann. Oncol.*, (15): 460-466, 2003.
- [18] T., Aloia, M. Sebah, M. Plasse, K. Vincent, LeviF, Giacchetti; D., Azoulay, H. Bismuth,; D. Costaing, and R., Adam Liver histology and surgical outcomes after preoperative chemotherapy with fluorouracil plus Oxaliplatin in colorectal cancerliver metastases. *J. clin. Oncol.*, (24): 4983-4990, 2006.
- [19] M. Karoui, C. Penna, and H.M., Amin, Influence of preoperative chemotherapy on the risk of major hepatoctomy for colorectal liver metastases. *Ann. Sug.*, (243): 1-7; 2006.
- [20] J.N.Vauthey, T.M. Pawlik and D.Ribero, Chemotherapy regimen predicts steatohepatitis and an increase in 90-day mortality after surgery fore hepatic colorectal metastes *J. clin. Oncol.*, (24):2065-2072, 2006.
- [21] M.M., Aloysius, A.M.; I.J. ZaitounBeckingham; K.R., Neal; G.P., Aithal,; E.M., Bessell and Lobo D.N. The pathological response to neoadjuvant chemotherapy with FOLFOX-4 for colorectal liver metastases: a comparative study *Virchows Arch.*; 2007, 451: 943-948.
- [22] K.S.N.G. Jennica, , J.U. Stefan, M. Naurang, M. Andrew, R Francis. , E.D. Sutherland; D Scot. , E. Scott and F.B. Oliver Colorectal liver metastases contract centripetally with a response to chemotherapy (A histomorphologic study). *American J.*, 112 (2): 362 - 371, 2007.
- [23] S. Kandutsch, M. Klinger, S. Hacker, F. Wrba, B. Gruenberger and T. Gruenberger Patterns of hepatotoxicity after chemotherapy for colorectal cancer liver metastases. *EJSO J.*, 34 (11): 1231-1236, 2008.